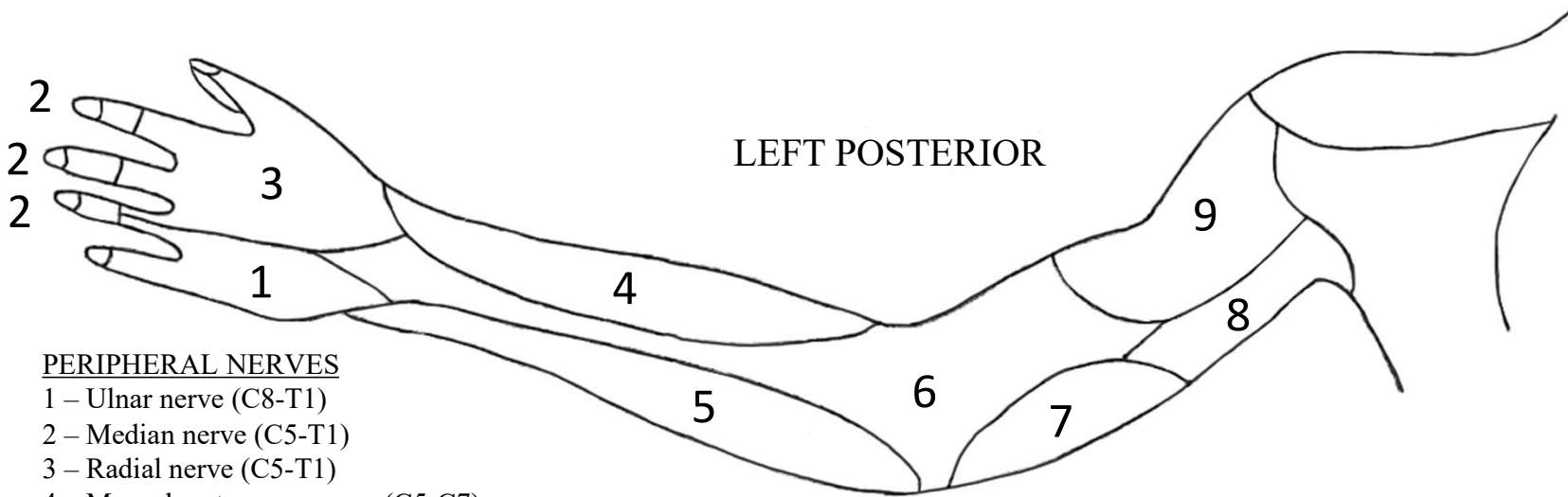


PACIFIC NORTHWEST UNIVERSITY OF HEALTH SCIENCES
SENSORY EVALUATION WITH PERIPHERAL NERVE DISTRIBUTION

DATE: _____

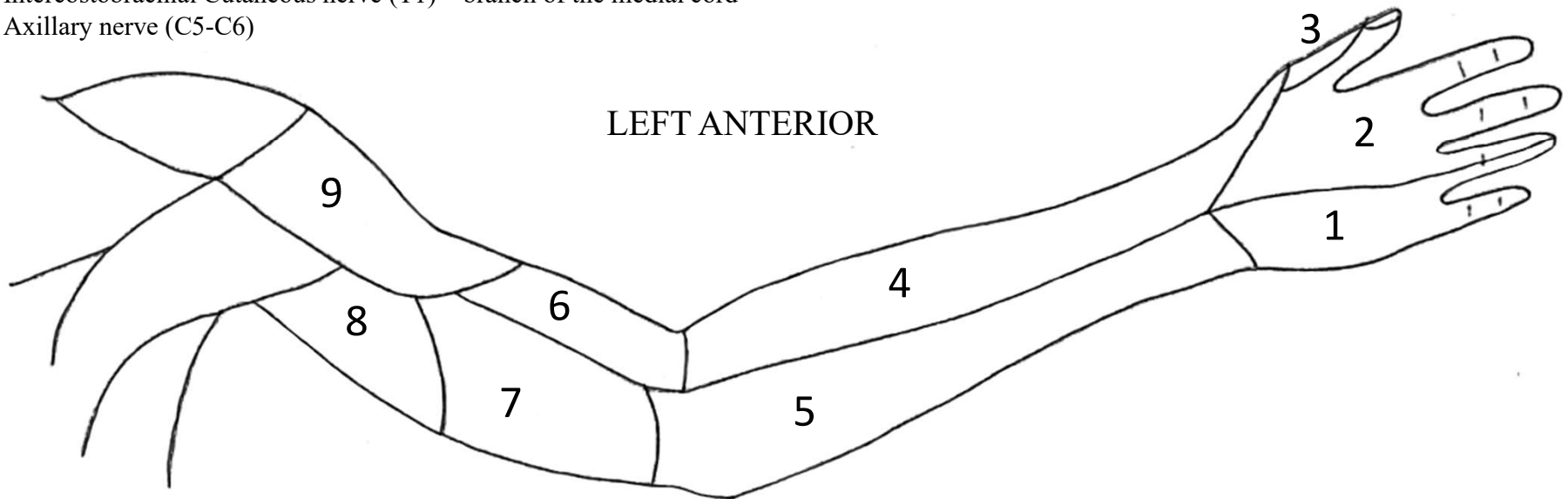
CLIENT: _____

EVALUATOR'S INITIALS: _____



PERIPHERAL NERVES

- 1 – Ulnar nerve (C8-T1)
- 2 – Median nerve (C5-T1)
- 3 – Radial nerve (C5-T1)
- 4 – Musculocutaneous nerve (C5-C7)
- 5 – Medial Antebrachial Cutaneous nerve (C8-T1) – branch of medial cord
- 6 – Posterior Brachial Cutaneous nerve (C5) – branch of radial n.
- 7 – Medial Brachial Cutaneous nerve (C8-T1) – branch of medial cord
- 8 – Intercostobrachial Cutaneous nerve (T1) – branch of the medial cord
- 9 – Axillary nerve (C5-C6)

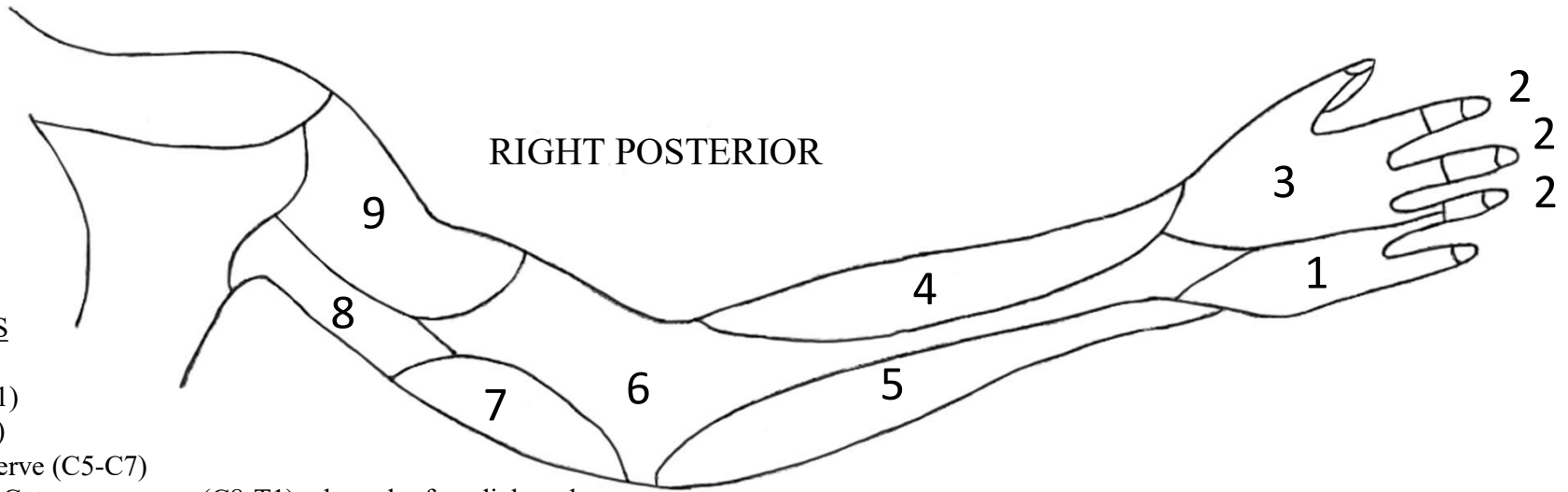


PACIFIC NORTHWEST UNIVERSITY OF HEALTH SCIENCES
SENSORY EVALUATION WITH PERIPHERAL NERVE DISTRIBUTION

DATE: _____

CLIENT: _____

EVALUATOR'S INITIALS: _____



PERIPHERAL NERVES

- 1 – Ulnar nerve (C8-T1)
- 2 – Median nerve (C5-T1)
- 3 – Radial nerve (C5-T1)
- 4 – Musculocutaneous nerve (C5-C7)
- 5 – Medial Antebrachial Cutaneous nerve (C8-T1) – branch of medial cord
- 6 – Posterior Brachial Cutaneous nerve (C5) – branch of radial n.
- 7 – Medial Brachial Cutaneous nerve (C8-T1) – branch of medial cord
- 8 – Intercostobrachial Cutaneous nerve (T1) – branch of the medial cord
- 9 – Axillary nerve (C5-C6)

